

3d advanced course on knee surgery
Val d'Isère 2010

Proximal tibia fractures – complex cases: porotic bone, distal extended lesion, multiple lower limb fractures

Prof. R.Seil
Dr. P. Brogard
Prof. T. Gerich

Centre de l'Appareil Locomoteur, de Médecine du Sport et de Prévention
Centre Hospitalier de Luxembourg – Clinique d'Eich

Goals ?

- Minimum soft-tissue damage
- Allow for fracture healing
- Allow for early mobilization
- Possibility of articular reconstruction
- Good conditions for later TKA



Osteoporotic fractures


Bone density

Age	Normal	Osteopenia	Osteoporosis
50-59 (27)	3 (11,1)	13 (48,2)	11 (40,7)
60-69 (24)	3 (12,5)	5 (20,8)	16 (66,7)
70-79 (36)	0	13 (36,1)	23 (63,9)
80-89 (65)	1 (1,6)	8 (12,3)	56 (86,1)
90-99 (16)	0	2 (12,5)	14 (87,5)
>100 (1)	0	0	1 (100)

- Fracture = alarm sign
- Signal to induce diagnostics & treatment
- Risk of later fractures can be reduced by 50 %

Mutschler W, Unfallchirurg 2005


Geriatric fractures



- Greater degree of comminution
- Difficult postoperative mobilization, but high necessity of mobilization
- Limited availability of autogenic bone
- Comorbidity (vascular)
- Proximal tibia: literature sparse

Krappinger D, JOT 2008

Bone defects




Autologous cancellous bone
Allografts
Synthetic materials

Norian SRS

82 years

Fractures of the proximal tibia in elderly patients



- Matched-pair analysis
- 15 patients > 60; 5 year FU
- Low-energy accidents
- Identical surgical treatment in both groups
- Higher loss of reduction
- 3-fold increase of OA
- Function, stability & pain: no difference
- Older group: lower Tegner activity score
- Satisfactory clinical result

Gerich T, Unfallchirurg 2001

Case 1

- ♀, 70 years
- Asymptomatic medial OA

Classification

Posterior split-impression

Case 1

Fibula osteotomy & tension-band

+ 6 months

Case 2

49 years, severe osteoporosis

Classification


Case 2

Spanning external fixator – knee in traction

Ligamentotaxis


49 years

Case 2




Bone grafting
& small locking plates:
medial
+
posteromedial
+
lateral

49 years





4 months postop 4 months postop

Case 3




- ♀ 86 years
- Severe osteoporosis


Case 3


Classification




D1
SPLIT FRACTURE




D2
ENTIRE CONDYLE




D3
RIM AVULSION



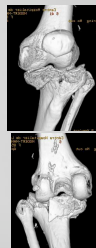
D4
RIM IMPRESSION



D5
4-PART FRACTURE




D6
RIGID/LAER




Case 3





Case 3





Small locking plates:
posterior,
posteromedial,
lateral
Bone allograft

+ 5 months



Osteoporotic fractures: summary

- Low-energy accidents
- Fracture-dislocations rare
- 2-stage procedure (ligamentotaxis)
- Understanding of fracture type
- Filling materials (≠ autografts)
- Higher loss of reduction (locking plates ?)
- 3-fold increase of OA
- Satisfactory clinical results

Complex, multi-stage proximal tibia & combined fractures

Multi-stage proximal tibia fractures

Epiphyseal
Metaphyseal
Diaphyseal

- Rare in comparison with tibial head or shaft fractures
- High-energy trauma, associated fractures
- High complication potential:
 - soft-tissues
 - compartment syndrome

Multi-stage proximal tibia fractures

Series of 24 cases:

- 19 → 3 stages; 5 → 2 stages
- Single injury: 10
- Combined injury: 4
- Severe polytrauma: 10
- Injury same limb requiring surgery: 11
- Knee ligament injuries: 6

Beck M, Unfallchirurg 2008

Conventional ORIF ?

High complication rate:

- Malalignment
- Pseudarthrosis
- Infections (local, osteomyelitis, arthritis)

Infections:

- Single plate: up to 32 %
- Double plate: up to 87 %


Moore TM, CORR 1988; Perry CR, JBJS – Am, 1984; Stokel EA, Orthopedics 1991; Young M, Orthop Rev 1994

Multi-stage proximal tibia fractures

Current options 1:

- Temporary external fixator
- Fracture reposition
- Temporary stabilization before final fixation
- Soft-tissue management

Multi-stage proximal tibia fractures




Current options 2:

Hybrid fixator

- Fracture reposition
- Comminuted fractures
- Soft-tissue management
- Specific complications (15%):
 - peroneal nerve injuries
 - intraarticular pin
 - pin infections

Hutson JH JOT, 1998
Mikulak SA CORR, 1998

Multi-stage proximal tibia fractures



Current options 3:

Internal fixation:


LISS plates & various approaches

Few complications:

- malalignment
- infections

Cole PA, Injury 2003
Schütz M, Injury 2003

Multi-stage tibial fractures: LISS experience

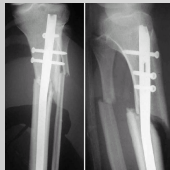


- Open fractures:	26 %
- Infections:	6 %
- Postoperative malalignment > 5°:	12 %
- Loss of correction > 5°:	3 %
- Healing rate at 6 months:	95 %

N=419

Beck M, 2009; Boldin 2006; Cole 2004; Egol 2004; Gosling 2005; Phisitkul P 2007; Ricci 2004; Schütz 2003; Stannard 2003 & 2004

Intramedullary stabilization ?




Technically difficult, especially if in association with tibial plateau fracture

32 proximal fractures

- 56% Valgus deformity > 5°
- 28% sagittal malpositioning

Lang GJ, Clin Orthop 1995
Freedman EL, Clin Orthop 1995

Extensor mechanism: early repair



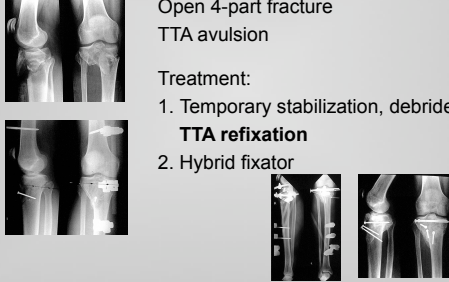
Dashboard injury
Open fracture
Tear of: patellar tendon, PCL, collaterals

Treatment:

1. Temporary stabilization, debridement & **patellar tendon repair**
2. ORIF with lateral LISS & bone grafting

From: Petersen W, Unfallchirurg 2006

Extensor mechanism: early repair




Open 4-part fracture
TTA avulsion

Treatment:

1. Temporary stabilization, debridement & **TTA refixation**
2. Hybrid fixator


Multi-stage proximal tibia fractures



4-part fracture

Center for Advanced Orthopedics, Department of Sports and Trauma, University Hospital of Würzburg

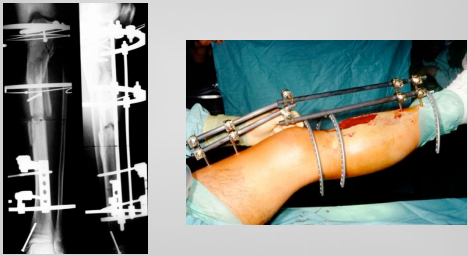
Multi-stage proximal tibia fractures



First operation

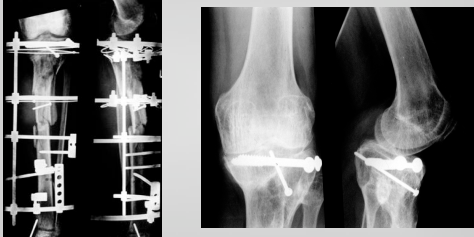
Center for Advanced Orthopedics, Department of Sports and Trauma, University Hospital of Würzburg

Multi-stage proximal tibia fractures



Center for Advanced Orthopedics, Department of Sports and Trauma, University Hospital of Würzburg

Multi-stage proximal tibia fractures




4 months

3 years


Center for Advanced Orthopedics, Department of Sports and Trauma, University Hospital of Würzburg

Multi-stage proximal tibia fractures



Center for Advanced Orthopedics, Department of Sports and Trauma, University Hospital of Würzburg


Floating knee



From: Petersen W, Unfallchirurg 2006

- Fracture dislocation of proximal tibia
- 1. external fixator
- 2. ORIF (LISS + Tomofix)

Center for Advanced Orthopedics, Department of Sports and Trauma, University Hospital of Würzburg



Complex injuries

Same principles:

1. Soft-tissue control
2. Temporary stabilization
3. Treatment strategy
4. Final fixation


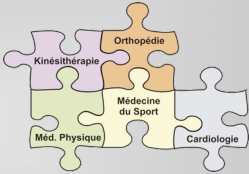
=> experience & teamwork approach !

Centre de Réhabilitation de Médecine du Sport de l'Université de Liège
Centre de Réhabilitation de Médecine du Sport de l'Université de Liège

Complex & multiple injuries: conclusions

- High-energy; fracture-dislocations
- 1. step: Immobilization
Reduction (external fixator, ligamentotaxis)
Soft-tissue management
- 2. step: Exact diagnosis (CT, 3-D reconstructions)
- 3. step: ORIF (various approaches, based on understanding of fracture)
- 4. step: Re-assess ligament/cartilage/meniscus status
- Little space for arthroscopic assisted internal fixation
- Create best possible conditions for later TKA

Centre de Réhabilitation de Médecine du Sport de l'Université de Liège
Centre de Réhabilitation de Médecine du Sport de l'Université de Liège

www.sportsmedicine-ch.lu